

**Accreditation Statement**

The University of Pittsburgh School of Medicine is accredited by the Accreditation Council for Continuing Medical Education (ACCME) to provide continuing medical education for physicians.

The University of Pittsburgh School of Medicine designates this enduring material for a maximum of 0.5 AMA PRA Category 1 Credits™. Each physician should only claim credit commensurate with the extent of their participation in the activity. Other health care professionals are awarded 0.05 continuing education units (CEU) which are equivalent to 0.5 contact hours.

**Disclosures**

Greg Bowden, MD, Edward A. Monaco III, MD, PhD, Ajay Niranjani, MD, MBA, and Svetlana Trofimova, MS, PA-C, have reported no relationships with proprietary entities producing health care goods or services.

L. Dade Lunsford, MD, is a consultant for AB Elekta and Insightec DSMB. Dr. Lunsford is a stockholder in AB Elekta.

Hideyuki Kano, MD, PhD, receives grant research support from Elekta.

**Instructions**

To take the CME evaluation and receive credit, please visit [UPMCPHYSICIANRESOURCES.COM/Neurosurgery](http://UPMCPHYSICIANRESOURCES.COM/Neurosurgery) and click on the course *Neurosurgery News Winter 2016*.

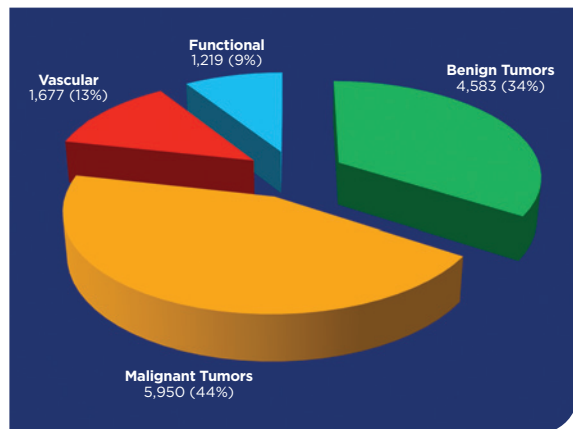
## The Evolution of the Gamma Knife at UPMC

In the late 20th century, Lars Leksell conceived of the Gamma Knife® in Sweden. The device non-invasively treats brain tumors, vascular malformations, and other neurological conditions by cross-firing approximately 200 gamma rays to a specific target, sparing the surrounding tissue. Below is a timeline of UPMC's history with this groundbreaking technology.

- ▶ **1987** — Presbyterian University Hospital installed the Gamma Knife model U, the first ever 201 Cobalt Source Gamma Knife in North America.
- ▶ **1990** — The spectrum of indications increased, and long-term Gamma Knife radiosurgery results showed high brain tumor control rates and successful closure of arteriovenous malformations (AVMs).
- ▶ **1992** — UPMC installed a newer version of the device, known as Gamma Knife model B. This model solved a previous issue of recharging the device's energy sources.



**Figure 2.** Leksell Gamma Knife Icon



**Figure 1.** Breakdown of indications treated by Gamma Knife radiosurgery from 1987 through 2015 at UPMC.

- ▶ **1996** — A third version of the Gamma Knife, which used robotics to successfully pinpoint the target, was installed at UPMC.
- ▶ **2006** — UPMC installed the Gamma Knife Perfexion, a larger, fully robotic unit with more efficient dose delivery. Indications increased to include brain metastases, deep skull base tumors, and malignant brain tumors.
- ▶ **2015** — Since installing its first Gamma Knife unit 28 years earlier, the team at UPMC treated nearly 13,500 patients (see Figure 1), published more than 400 peer-reviewed outcomes studies, and trained more than 1,800 professionals in methods and long-term outcomes of Gamma Knife radiosurgery.
- ▶ **2016** — UPMC welcomes the state-of-the-art Leksell Gamma Knife Icon (see Figure 2). This model is equipped with an on-board CT scanner and microradiosurgery capabilities, further advancing the successful treatment of brain tumors, AVMs, and various neurological conditions.

**Free Online CME**

To take the CME evaluation for this issue, visit our education website: [UPMCPHYSICIANRESOURCES.COM/Neurosurgery](http://UPMCPHYSICIANRESOURCES.COM/Neurosurgery).

# Chairman's Message

## One Size Does Not Fit All



One feature of UPMC's Department of Neurological Surgery that I am most proud of is that physicians in our department are able to provide precise, tailored care to each patient. Our patients have access to an arsenal of experts from a broad spectrum of subspecialties. This deep and varied expertise provided by our physicians — in a highly collaborative

environment — allows us to confidently diagnose both common and rare conditions. By identifying critically important nuances and details of each patient's condition, we are able to map out optimal treatment strategies.

A key factor in helping us reach this unparalleled level of performance is our long-standing tradition of innovation and leadership. By developing novel approaches for the management of complex and previously untreatable conditions, we are reducing the morbidity and mortality associated with both the natural history as well as the treatment for many conditions.

Our innovation and leadership can clearly be seen in this issue of our newsletter as we spotlight UPMC's remarkable Gamma Knife® program, which was established more than 29 years ago and has since remained at the forefront of stereotactic

radiosurgery treatment and innovation. This leadership in innovation is replicated in our programs for cranial nerve microvascular decompression (MVD) and expanded endoscopic endonasal approaches (EEA) for skull base lesions. Adding high-definition fiber tractography (HDFT) to our diagnostic armamentarium has further improved our ability to perform safer and more effective surgical procedures.

At UPMC's Department of Neurological Surgery, we have the surgical expertise and advanced technology to provide precise, patient-specific care. Our experienced surgeons — working as part of an innovative, multidisciplinary team — can confidently diagnose even the most difficult conditions and map out an effective treatment strategy that is highly personalized to the needs of the patient.

Expertise has long been the intellectual cornerstone of our department. Innovation has been the preeminent driving force.

*Robert M. Friedlander, MD, MA*

*Chairman and Walter E. Dandy Professor of Neurological Surgery  
Co-Director, UPMC Neurological Institute*

## Faculty

### Chairman

Robert M. Friedlander, MD, MA

### Professors

C. Edward Dixon, PhD  
Peter C. Gerszten, MD, MPH  
L. Dade Lunsford, MD  
John J. Moossy, MD  
David O. Okonkwo, MD, PhD  
Ian F. Pollack, MD  
Mingui Sun, PhD

### Associate Professors

Jeffrey Balzer, PhD  
Johnathan Engh, MD  
Juan C. Fernandez-Miranda, MD  
Paul A. Gardner, MD  
D. Kojo Hamilton, MD  
Adam S. Kanter, MD, FAANS  
Ajay Niranjani, MD, MBA  
Raymond F. Sekula Jr., MD, MBA  
Parthasarathy D. Thirumala, MD  
Elizabeth C. Tyler-Kabara, MD, PhD

### Assistant Professors

Nduka Amankulor, MD  
David J. Bissonette, PA-C, MBA  
(Executive Administrator)  
Diane L. Carlisle, PhD  
Donald J. Crammond, PhD  
Andrew F. Ducruet, MD  
Avniel Ghuman, PhD  
Paola Grandi, PhD  
Stephanie Greene, MD  
Miguel Habeych, MD, MPH  
Brian Jankowitz, MD  
Edward A. Monaco III, MD, PhD  
Ava Puccio, PhD, RN  
R. Mark Richardson, MD, PhD  
Mandeep Tamber, MD, PhD

### Clinical Professors

Adnan A. Abila, MD  
Matt El-Kadi, MD, PhD  
Joseph C. Maroon, MD  
Daniel A. Wecht, MD, MSc

### Clinical Associate Professors

Michael J. Rutigliano, MD, MBA  
David S. Zorub, MD

### Clinical Assistant Professors

J. Brad Bellotte, MD  
Daniel M. Bursick, MD  
David L. Kaufmann, MD  
Vincent J. Miele, MD  
Monte B. Weinberger, MD

### Research Associate Professor

Hideyuki Kano, MD, PhD

### Research Assistant Professors

Yue-Fang Chang, PhD  
Wendy Fellows-Mayle, PhD  
Esther Jane, PhD  
Wenyan Jia, PhD  
Daniel Premkumar, PhD  
Hong Qu Yan, MD, PhD

### Clinical Instructors

Jeffrey W. Bost, PA-C  
Erin E. Paschel, PA-C

### Chief Residents

Gurpreet S. Gandhoke, MD  
Ali Kooshkabadi, MD  
Robert Miller, MD

## Contact Us

Brain Function & Behavior  
412-647-7744

Brain Tumors  
412-647-2827

Carotid Disease  
412-647-2827

Cerebrovascular  
412-647-2827

Clinical Neurophysiology  
412-647-3450

Cranial Nerve Disorders  
412-647-3920

Donations  
412-647-7781

Endonasal Surgery  
412-647-6778

Endovascular  
412-647-7768

Gamma Knife®  
412-647-7744

MEG Brain Mapping Center  
412-648-6425

Movement Disorders  
412-647-7744

Neurosurgical Oncology  
412-647-8312

Pediatric Neurosurgery  
412-692-5090

Referrals  
412-647-3685

Residency Program  
412-647-6777

Spine  
412-802-8199

Spine Radiosurgery  
412-647-9786

UPMC Mercy Neurosurgery  
412-471-4772

### Department of Neurological Surgery

UPMC Presbyterian  
Suite B-400  
200 Lothrop St.  
Pittsburgh, PA 15213

**Editor:** Peter C. Gerszten,  
MD, MPH

**Website:** [neurosurgery.pitt.edu](http://neurosurgery.pitt.edu)

**Email:** [neuroinfo@upmc.edu](mailto:neuroinfo@upmc.edu)

# Trigeminal Neuralgia Radiosurgery

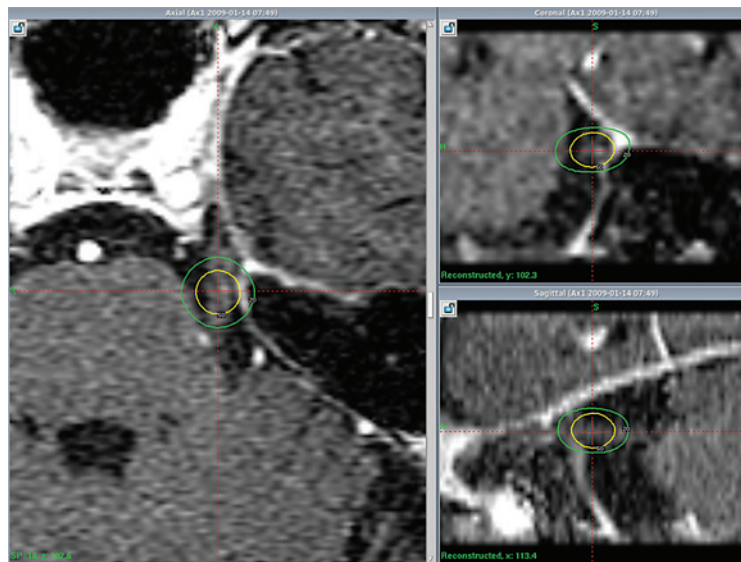
by **Ajay Niranjjan, MD, MBA, Edward A. Monaco III, MD, PhD, Svetlana Trofimova, MS, PA-C, L. Dade Lunsford, MD**

Gamma Knife® stereotactic radiosurgery (SRS) is a minimally invasive surgical approach for managing medically refractory trigeminal neuralgia (TN). The goal of Gamma Knife SRS for TN is to eliminate or reduce face pain in order to improve patients' quality of life, and numerous reports have documented its efficacy and safety.

Because SRS is the least invasive procedure for TN, it is a good treatment option for patients with other high-risk medical conditions and those who do not want to accept the greater risk associated with other surgical procedures.

Over the past 28 years, 1,218 patients have undergone Gamma Knife SRS for TN at UPMC. In our retrospective review of 503 patients who underwent SRS for management of refractory TN (see Table 1), 449 patients (89 percent) experienced initial pain relief at a median latency of one month. After one year, 73 percent of patients were pain free (with or without medications), and 80 percent had pain control (pain improved but adequately controlled with medications). Patients with typical TN (no additional symptoms) who did not undergo prior surgery,

as well as patients with a symptomatic duration of three years or fewer, experienced faster initial pain response, including complete or some pain relief. One hundred ninety-three (43 percent) of 450 patients who achieved initial pain relief reported some recurrence at a median of 50 months after initial relief. Fifty-three patients (12 percent) developed new facial numbness. These symptoms resolved in 17 patients. Patients who developed sensory loss had better long-term pain control (78 percent at five years).



**Figure 1.** Contrast enhanced axial MRI with coronal and sagittal reconstruction showing Gamma Knife radiosurgery dose plan for left-sided trigeminal neuralgia. A 4 mm collimator is used to deliver 80 Gy central dose. The 50 percent isodose line (yellow) is 2 to 3 mm away from the surface of brain stem.

Repeat radiosurgery was performed for 193 patients (43 percent). After one year, 26 percent of these patients were completely pain free and 78 percent were pain free with or without medications. The probability of maintaining adequate pain relief was 80 percent after one year and 74 percent after two years.

The role of Gamma Knife SRS in the management of medically refractory TN has evolved significantly over the past two decades. SRS is a minimally invasive procedure and is associated with a 60 to

90 percent rate of pain relief in patients with medically refractory TN. Early intervention with SRS as the initial surgical procedure for management of refractory TN is associated with faster, better, and enduring pain relief.

SRS for Trigeminal Neuralgia	# of Patients	Central Dose (Gy)	FUP Months	Initial (BNI I-IIIb) Pain Relief	Median Time to Pain Relief (weeks)	Recurrence Rate (%)	Pain Control Rate (%)			Sensory Dysfunction (%)
							1-yr	2-yr	5-yr	
Idiopathic TGN	503	80		89	4	43	80	71	46	10.5
Repeat SRS	119	70	48	87	6		87.8	69.8	44.2	21
Vertebrobasilar ectasia	20	80	29	75	5	60	53	38	10	10
MS-Related TGN	37	80	57	97			82.6	73.9	54	5.4

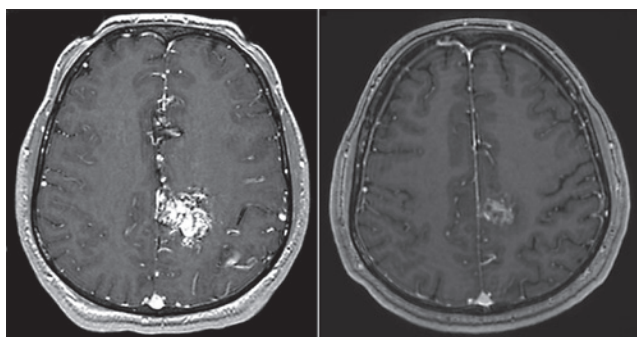
**Table 1.** Summary of patients who have undergone Gamma Knife SRS for TN at UPMC.

## Gamma Knife Radiosurgery for Arteriovenous Malformations

by Greg Bowden, MD

Arteriovenous malformations (AVMs) are vascular abnormalities resulting in a poorly formed tangle of veins and arteries called a nidus. These lesions are relatively uncommon, with a prevalence of 18 per 100,000 people. Two-thirds of AVMs are diagnosed in patients under the age of 40. AVMs can be associated with headaches, seizures, neurological deficits, and bleeds. For those with an AVM, the risk of a bleed is approximately 2 to 4 percent per year, which can result in significant neurological deficit in 30 percent and death in 10 percent of those patients.

Management options for AVMs have evolved over time and have included open surgical resection, endovascular embolization, and



**Figure 1.** Axial MRI+GAD pre-treatment (left image) and follow-up scan at four years (right image).

radiosurgery. However, the underlying goal of treatment remains the same: complete closure of the abnormal vascular nidus. Although some physicians advocate observing these lesions as opposed to treating them, the risk of bleeding remains, and over a patient's projected lifespan, this risk can approach 100 percent based on the age at diagnosis.

The Center for Image-Guided Neurosurgery at UPMC has treated almost 1,500 patients with AVMs. More than 87,000 Gamma Knife® procedures for AVMs have been conducted worldwide.

Gamma Knife radiosurgery is a minimally invasive approach for eliminating an AVM. Gamma rays are focused with sub-millimeter precision on the AVM nidus based on MRI and vascular imaging. This allows for outpatient AVM treatment while minimizing risk to the surrounding brain. The AVM slowly shrinks, and the blood flow through the nidus stops over an average interval of three years (see Figure 1). Based on our data, AVM closure rates after a single Gamma Knife procedure range from 60 to 90 percent of patients, depending on AVM characteristics such as volume, dose delivered, location, nidus type, and patient age.

Since 1987, UPMC has been a world leader in Gamma Knife radiosurgery and teaches medical personnel from around the world how to use this technology. Our dedicated, multidisciplinary team of neurosurgeons, vascular specialists, radiation oncologists, medical physicists, and nurses is highly experienced in AVM radiosurgery.

## Stereotactic Radiosurgery for Tremor

by Ajay Niranjana, MD, MBA, Edward A. Monaco III, MD, PhD, Svetlana Trofimova, MS, PA-C, L. Dade Lunsford, MD

Tremor is a common movement disorder with disabling effects on daily activities. Tremors are initially managed with medication, which is helpful for some patients, but many individuals either derive no benefit from it or become unresponsive.

For elderly patients or those with medical comorbidities, stereotactic radiosurgical thalamotomy using the Gamma Knife® is an

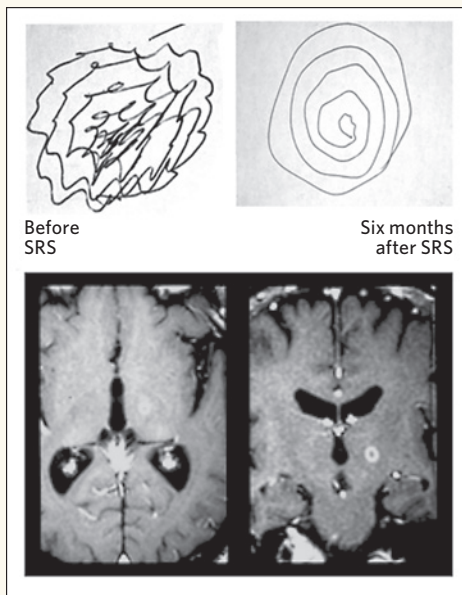
effective option. Radiosurgery is a minimally invasive treatment that is ideal for older patients or those with significant additional risk factors. The radiobiological effect of the radiosurgical lesion is unique. The effect consists of a limited central target necrosis (3 to 4 mm in diameter).

Over a 28-year period, 166 patients have undergone Gamma Knife stereotactic radiosurgery (SRS) for movement disorder at UPMC. The results of our studies are listed in Table 1.

(Continued on Page 5)

SRS for Tremor	# of Patients	Central Dose (Gy)	FUP Months	Improvement (%)	No Change (%)	Adverse Effects (%)
SRS for Tremor	86	140	23	81	19	5
SRS for Essential Tremor	31	140	36	88	12	65
SRS for MS Related Tremor	6	140	27.5	100	0	

**Table 1.** Stereotactic radiosurgery for tremor study.



## Tremor (Continued from Page 4)

In our recent study of 86 patients, SRS proved to be effective in improving medically refractory tremor associated with essential tremor, Parkinson's disease, and multiple sclerosis. In 70 patients (81 percent), at least one of the assessed scores was improved following SRS. The Fahn-Tolosa-Marin clinical tremor rating scale was used to assess preoperative and postoperative tremor, handwriting, and ability to drink from a cup. Overall, the preoperative and postoperative mean for tremor, handwriting, and drinking scores showed significant improvement.

Our data suggest that SRS for tremor can have significant benefits, particularly for patients who are elderly or too high-risk to undergo thalamic deep brain stimulation. (see Figure 1). The minimally invasive nature of SRS makes it an excellent procedure for elderly patients with disabling tremor and those with other increased surgical risk factors.

< **Figure 1.** Scans at bottom show a 77-year-old man with 20-year tremor history. Drawing at upper left shows result of patient's effort to draw a spiral before treatment, with evidence of severe tremor. Drawing at upper right shows result of same patient's effort to draw same spiral six months after stereotactic radiosurgery.

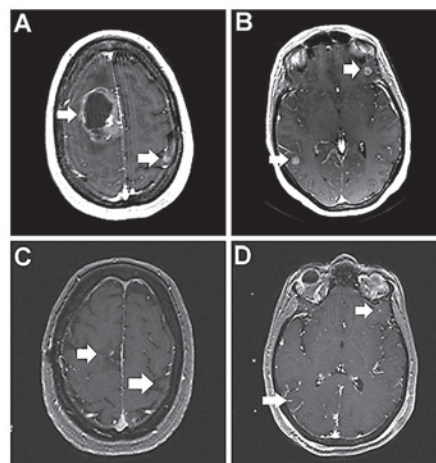
## When Cancer Spreads to the Brain

by Edward A. Monaco III, MD, PhD

Brain metastases can be a devastating diagnosis, but they do not have to be. Annually, about half a million people within the United States are diagnosed with brain metastases. Historically, this diagnosis, even of a solitary brain metastasis, portended a poor prognosis due to the limited treatment options available. Corticosteroid treatment alone allowed for survival of around one month. Whole brain radiation therapy (WBRT) extended survival to three to six months on average. Sparingly, craniotomy was and is used for select patients with surgically accessible tumors causing symptomatic mass effect. In the past, most patients died from progressive growth of the metastatic brain tumor, but new advances in technology have greatly improved treatment options.

The Gamma Knife® is used to treat a number of intracranial pathologies, with brain metastases representing the highest volume of diagnoses. UPMC has treated nearly 6,000 patients with brain metastases since the introduction of the Gamma Knife to the facility in 1987. Modern cancer therapy allows patients with cancer to live longer, better lives.

As physicians who care for them, we are obliged to carefully consider the consequences of our treatments.



**Above:** A 49-year-old woman with a long smoking history presented to UPMC Presbyterian with a headache and weakness in her left side. An MRI scan revealed several brain metastases including a large right frontal tumor (A and B). A CT scan of the chest demonstrated a lung tumor. She underwent a craniotomy for the large tumor and, during the same admission, had Gamma Knife treatment to the tumor bed and to her other brain tumors. She returned to normal neurological functioning within one week of treatment. Her tumors responded very well, with many shrinking or disappearing completely (C and D).

Regardless of the primary source of the cancer, the Gamma Knife has a proven track record of success. Tumor control rates are greater than 80 percent in most cases. In combination with more effective systemic therapy, quality life expectancies are now measured in years, instead of weeks or months. Outcomes after Gamma Knife radiosurgery have been defined in multiple clinical trials and extensive research over the past two decades. Routinely, patients harboring 10, 20, or even more tumors are successfully treated in a single, minimally invasive outpatient procedure. Unlike surgery or WBRT, Gamma Knife procedures do not interrupt ongoing systemic chemo or radiation therapy.

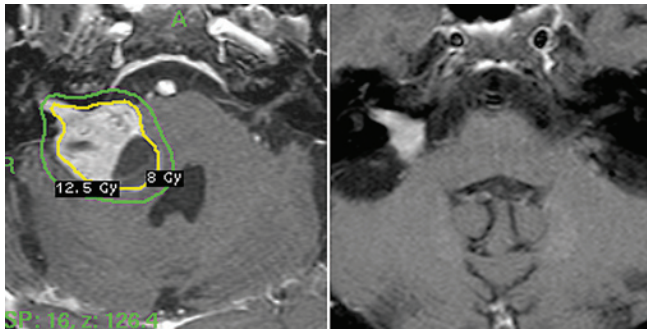
After almost three decades of pioneering experience at UPMC, the Gamma Knife has proven to be a minimally invasive, highly effective, safe, and convenient treatment strategy for patients whose cancer has spread to the brain.

## Gamma Knife Radiosurgery for Vestibular Schwannomas

by Hideyuki Kano, MD, PhD

Vestibular schwannomas, also known as acoustic neuromas, are benign tumors arising from the vestibulocochlear nerve sheath. These tumors are typically diagnosed early because of the widespread availability of MRI tests. The most common symptoms include tinnitus, hearing loss, or equilibrium disorders.

Gamma Knife® stereotactic radiosurgery is a well-established alternative to both continued observation and microsurgical removal. An observation strategy was first proposed for elderly



**Figure 1.** Gamma Knife planning: (Left) 53-year-old male right vestibular schwannoma patient with brainstem compression. (Right) Four-year follow-up MRI image. Tumor was significantly smaller in size.

patients or those with significant medical comorbidities who have an estimated lifespan of less than the growth/symptom progression rate of the tumor.

Hearing loss may progress even without imaging-defined growth. In our 28-year experience, we have observed that 70 percent of patients have measurable growth within five years, increasing to more than 95 percent after 10 years.

Gamma Knife stereotactic radiosurgery for vestibular schwannoma has been practiced for more than 40 years at various worldwide centers. Over the past 28 years, UPMC has treated nearly 1,800 vestibular schwannomas using Gamma Knife radiosurgery. Long-term outcome results have established the Gamma Knife procedure as an important, minimally invasive alternative to resection.

Stereotactic radiosurgery is likely the most common procedure performed for smaller vestibular tumors. Recent reports suggest a tumor control rate ranging from 93 to 100 percent after radiosurgery. Tumor shrinkage is noted in the majority of patients within five years (see Figure 1).

Pre-radiosurgery hearing can now be preserved in 60 to 90 percent of patients. Facial nerve function can now be preserved in virtually all patients. In rare cases of late tumor growth, repeat Gamma Knife radiosurgery has proven successful.

## Gamma Knife Radiosurgery for Meningiomas

by L. Dade Lunsford, MD

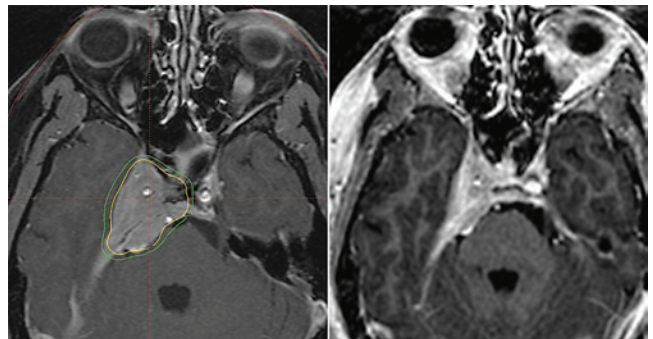
During the 28 years of our experience with Gamma Knife® radiosurgery at UPMC, we have treated almost 5,000 benign tumors of the skull base, or tumors derived from the brain lining surfaces.

Meningiomas are among the most frequent brain tumors encountered in the United States. Such tumors often present in critical brain regions that prevent complete resection with an acceptable risk. At UPMC's Center for Image-Guided Neurosurgery, we have treated more than 1,800 patients with meningiomas using Gamma Knife radiosurgery.

Long-term follow-up studies now confirm that radiosurgery can achieve tumor growth control in more than 85 to 90 percent of meningiomas while preserving or improving current neurological function in treated patients. Used in certain patients as an alternative to more invasive surgery by craniotomy or transnasal surgery, it is also effective in patients whose tumors have not been completely removed, or have recurred after prior surgery. Symptomatic or growing meningiomas involving the petroclival

skull base or cavernous sinus (see Figure 1) are especially difficult to remove surgically without new neurological deficits.

Patients undergo a single wheels-in-to-wheels-out image-guided procedure under mild sedation as an outpatient. Demonstrated outcomes include reduced cost, faster return to employment, and enhanced long-term quality of life.



**Figure 1.** (Left) Gamma Knife radiosurgery dose plan for a cavernous sinus region meningioma. (Right) Four-year follow-up MRI showing tumor shrinkage.

## News & Notes

### Lunsford Named Cushing Award Recipient

**L. Dade Lunsford, MD**, was selected as the 2016 recipient of the American Association of Neurological Surgery (AANS) Cushing Award for Technical Excellence and Innovation in Neurosurgery. The award recognizes the recipient's technical prowess and skill and/or innovation in the development of new procedures that have become part of the arsenal neurosurgeons use to treat disease or trauma.

The AANS cited Dr. Lunsford's "ability to improve the delivery of neurosurgical care by enhancing safety and efficacy and by making the field of neurosurgery safer, more accessible, more efficient and more effective." The award is one of the highest recognitions a neurosurgeon can receive.

### Sekula Edits Book on MVD Surgery

**Raymond F. Sekula Jr., MD, MBA**, is co-editor of the newly released first-edition textbook, *Microvascular Decompression Surgery*. The book provides an update on MVD surgery, an effective remedy for cranial nerve hyperexcitability disorders including hemifacial spasm, trigeminal neuralgia, and glossopharyngeal neuralgia.

The book's publisher, Springer, notes, "The authors describe in detail those steps of the process that need the most attention in order to achieve an excellent postoperative outcome, including positioning, craniectomy, approach and identification of the culprit, etc. Though it primarily focuses on surgical principles and technical nuances, the book also addresses the intraoperative electrophysiologic monitoring and pathogenesis of hemifacial spasm and trigeminal neuralgia."

Co-editors of the book are Shi-Ting Li, MD, PhD, and Jun Zhong, MD, PhD, from XinHua Hospital and Shanghai Jiao Tong University School of Medicine, in Shanghai, China.

### Fernandez-Miranda Contributes to *Gray's Anatomy*

**Juan C. Fernandez-Miranda, MD**, completed a comprehensive update of the "Intracranial Anatomy" chapter in the newest edition of *Gray's Anatomy: The Anatomical Basis of Clinical Practice*, the renowned anatomical reference text used by medical practitioners and students around the world. The updated chapter now provides a more accurate and practical description of the intracranial structures for cranial and skull base anatomists and surgeons.

### Congratulations

PGY-3 resident **David Salvetti, MD**, received the best presentation award at the 11th annual University of Pittsburgh Department of Neurological Surgery Stuart Rowe Society Lectureship and Resident Research Day, on October 21, for his presentation, "Preoperative Prealbumin as an Indicator of Postoperative Infection Risk in Spine Surgery." PGY-5 resident **Gregory Weiner, MD**, received a runner-up award for his presentation, "Prophylactic Antiepileptic Medications and Seizure Incidence Following Subarachnoid Hemorrhage."

**Parthasarathy Thirumala, MD**, was elected a fellow member of the American Academy of Neurology.

### Among the Best in Academic Output

The University of Pittsburgh Department of Neurological Surgery ranked among the top five neurosurgical residency programs in the country in terms of academic publishing output of faculty, according to an in-depth, five-year study published online by the *Journal of Neurosurgery* in September.

In the study, researchers from Tennessee and Oregon used bibliometrics — the statistical analysis of written publications — to calculate the objective impact of scholarly papers. The results showed that the University of Pittsburgh Department of Neurological Surgery had the third-highest score of 103 neurosurgical residency programs across the United States for papers published by its faculty from 2009 through 2013.

### Special Lectures and Appearances

**Paul Gardner, MD**, and **Carl Snyderman, MD, MBA**, served as guest faculty at the Pre-Congress Workshop of the Annual Conference of the Skull Base Society of India, held in Bangalore, India on October 9 and 10; the Endoscopic Base of Skull Surgery Course, held in Kerala, India from October 11 to October 13; and the Turkish Neurosurgical Society Skull Base Meningioma Conference, held in Istanbul, Turkey on December 11 and 12. During the courses in Kerala and Istanbul, they also performed live surgery demonstrations.

**Robert Friedlander, MD**, and **Raymond F. Sekula Jr., MD, MBA**, were special guest lecturers at the National Centre for Neurosurgery in Astana, Kazakhstan from November 2 to November 5, where they also performed surgery.

Dr. Sekula was also an honored guest lecturer at La Sociedad Ecuatoriana de Neurocirugia, in Guayaquil, Ecuador on September 25.

### In the News

**Brian Jankowitz, MD**, discussed strokes and how to treat them on the *KDKA Radio Morning News Show* with Larry Richert and John Shumway on October 26.

**David O. Okonkwo, MD, PhD**, was quoted in the *Pittsburgh Post-Gazette* on October 17, as well as numerous other media outlets, regarding findings from the recent UPMC Concussion Conference, concluding that rest may not be the best option for concussion patients.

**Joseph C. Maroon, MD**, was a guest on KDKA-TV's *Pittsburgh Today Live* morning talk show on October 11. He discussed tips for living a healthy life. Dr. Maroon also authored a *livestrong.com* article, "10 Tips to Live Healthier and Longer," which was published on December 7. Additionally, he was noted in a *Pittsburgh Post-Gazette* article on September 23 that detailed how National Football League teams are monitoring the health of players during games.

"Network Effects of Deep Brain Stimulation," a review article authored by **R. Mark Richardson, MD, PhD**, and his staff at the Brain Modulation Laboratory, was chosen for the November cover of the *Journal of Neurophysiology*.

## UPMC Opens New Elekta-Funded Educational Center

In the fall of 2015, UPMC completed construction of a new educational center adjacent to the current Gamma Knife® units on the first floor of UPMC Presbyterian. The center has state-of-the-art teaching and computer projection technologies that can facilitate both local educational and telemedicine conferences. Since 1995, UPMC has held 111 CME-approved educational courses on Gamma Knife radiosurgery for surgeons, radiation oncologists, and medical physicists. More than 1,800 medical professionals have been trained in the practice of stereotactic radiosurgery.



**Above:** L. Dade Lunsford, MD, lectures at the Principles and Practice of Gamma Knife Radiosurgery course in the new educational center at UPMC Presbyterian, made possible in part by Elekta.

### Free Online CME

To take the CME evaluation for this issue, visit our education website: [UPMCPhysicianResources.com/Neurosurgery](http://UPMCPhysicianResources.com/Neurosurgery).

A world-renowned health care provider and insurer, Pittsburgh-based UPMC is inventing new models of accountable, cost-effective, patient-centered care. It provides more than \$888 million a year in benefits to its communities, including more care to the region's most vulnerable citizens than any other health care institution. The largest nongovernmental employer in Pennsylvania, UPMC integrates 60,000 employees, more than 20 hospitals, more than 500 doctors' offices and outpatient sites, a 2.8-million-member health insurance division, and international and commercial operations. Affiliated with the University of Pittsburgh Schools of the Health Sciences, UPMC ranks No. 13 in the prestigious *U.S. News & World Report* annual Honor Roll of America's Best Hospitals. For more information, go to [UPMC.com](http://UPMC.com).

UPMC is proud to be the only hospital in western Pennsylvania to be named to *U.S. News & World Report's* prestigious national Honor Roll for excellence in 15 specialty areas, including neurology and neurosurgery. For more information about our programs, continuing medical education, Video Rounds, news, and events, please visit [UPMCPhysicianResources.com/Neurosurgery](http://UPMCPhysicianResources.com/Neurosurgery).

